



Ganglion Cysts

What you need to know about your condition

This handout describes the cause, symptoms, diagnosis, and treatment of ganglion cysts.

Ganglion cysts are common. They are lumps within the hand and wrist that arise from a joint or tendon. The most common places for cysts to form are:

- On top of the wrist.
- Base of the finger on the palm side.
- Top of the end finger joint of the finger.

Cause of Ganglion Cysts

The cause of ganglion cysts is unknown. The cysts form due to joint or tendon irritation or mechanical changes. These cysts are not cancerous and will not spread to other areas.

Signs and Symptoms

These cysts form adjacent to joints or tendon. It may change in size or shape. Cysts are often filled with a watery/jelly-like substance.

Diagnosis

Based on the location of the lump and the clinic appearance, typically, cysts are firm, nodules that are tender to applied pressure. Your doctor may request X-rays or an MRI to check for problems in adjacent joints. Cysts at the end joint of the finger often have arthritic bone spurs associated with them.

Surgery

Non-surgical Treatments

- Observation if the cysts are painless.
- If the cysts become painful, you may use splints and anti-inflammatory medicines to decrease pain during or from activities.

Questions?

Call 206-598-4263

Your questions are important. Call your doctor or health care provider if you have questions or concerns. UWMC clinic staff are also available to help at any time during clinic hours.

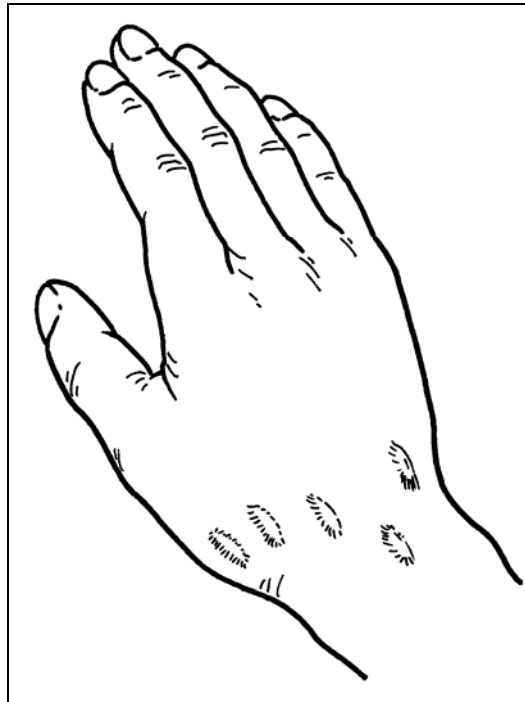
UWMC Hand Center:
206-598-HAND

- Your doctor may remove fluid from the cysts to decompress them and inject a steroid. This requires placing a needle into the cysts. This procedure can be done in most office settings.

Surgical Treatments

- Surgery involves removing the cysts along with a portion of the joint capsule or tendon sheath. Wrist ganglion cysts may be treated with either the traditional open technique or with an arthroscopic technique. Both techniques provide good results.

Surgical treatments are generally successful, although ganglion cysts may recur.



Possible locations of ganglion cysts.

Illustration from *Principles of Hand Surgery and Therapy* by Thomas E. Trumble, M.D., W.B. Saunders, 2000.

UNIVERSITY OF WASHINGTON
MEDICAL CENTER
UW Medicine

Orthopaedics/UWMC Hand Center

Box 354740

4245 Roosevelt, Way. Seattle, WA 98105

206-598-HAND (4263)

www.orthop.edu/hand