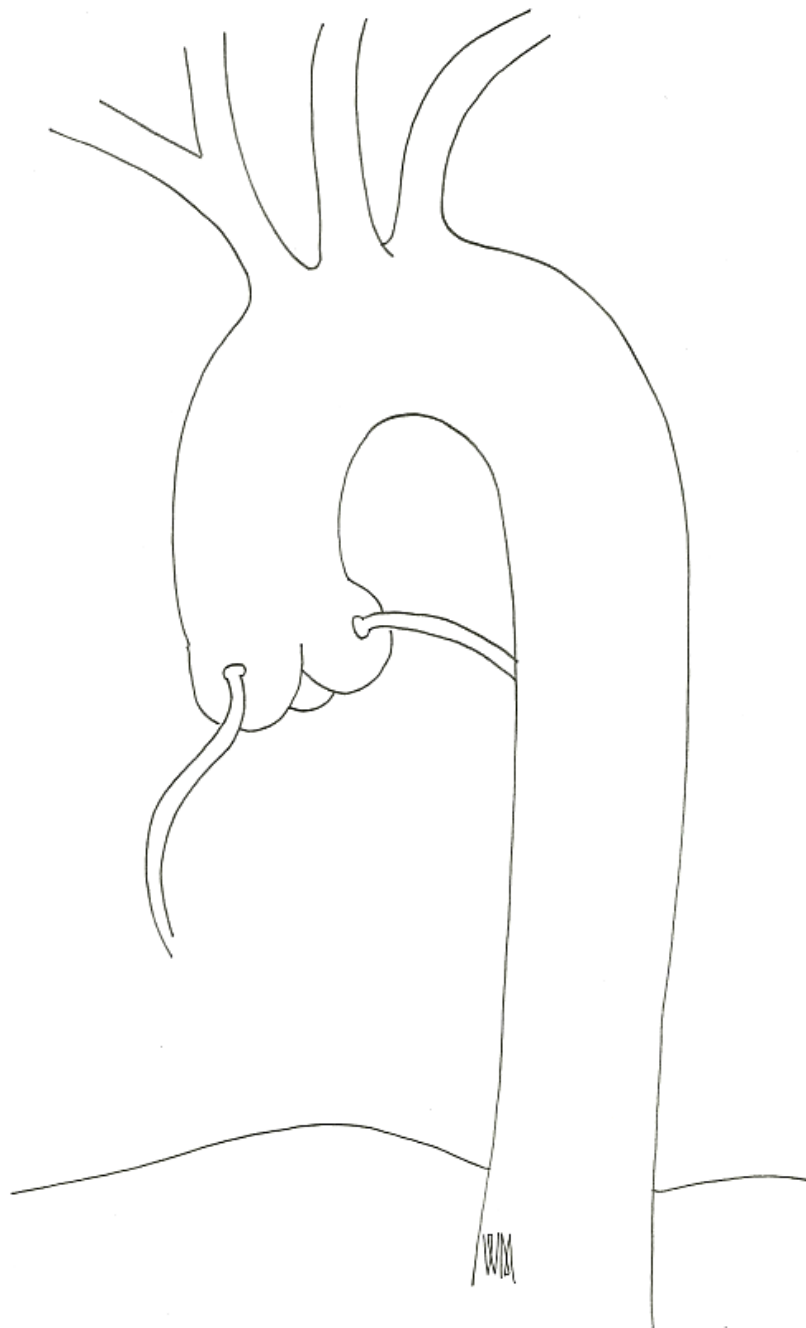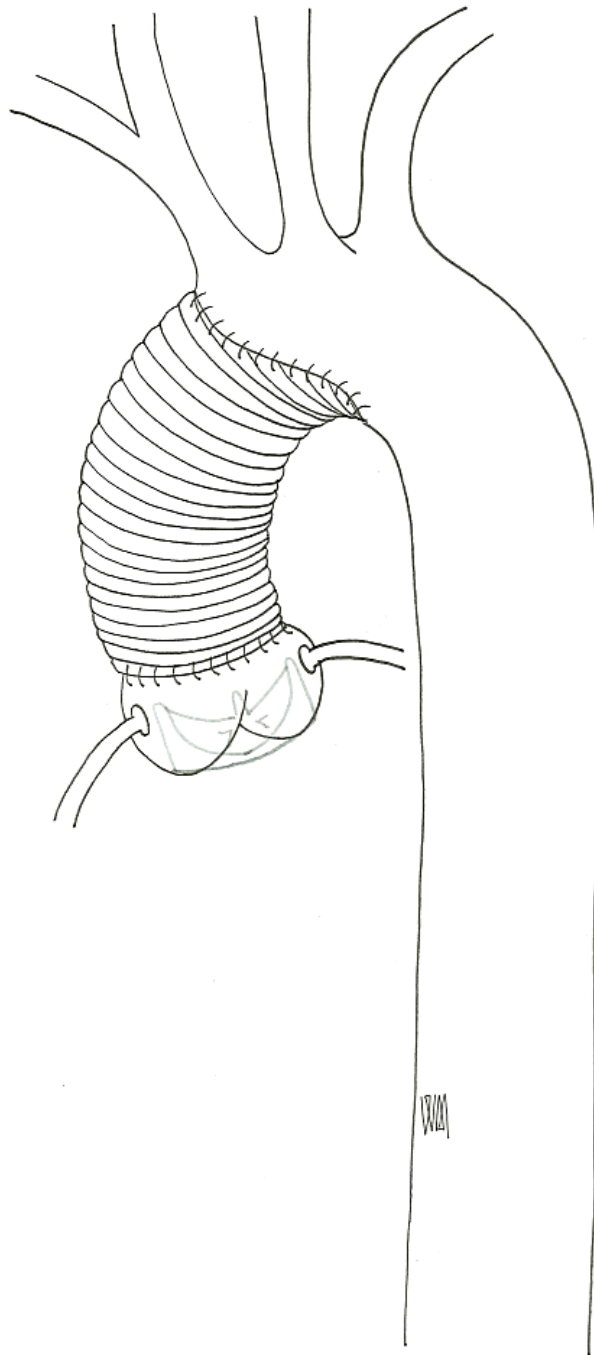


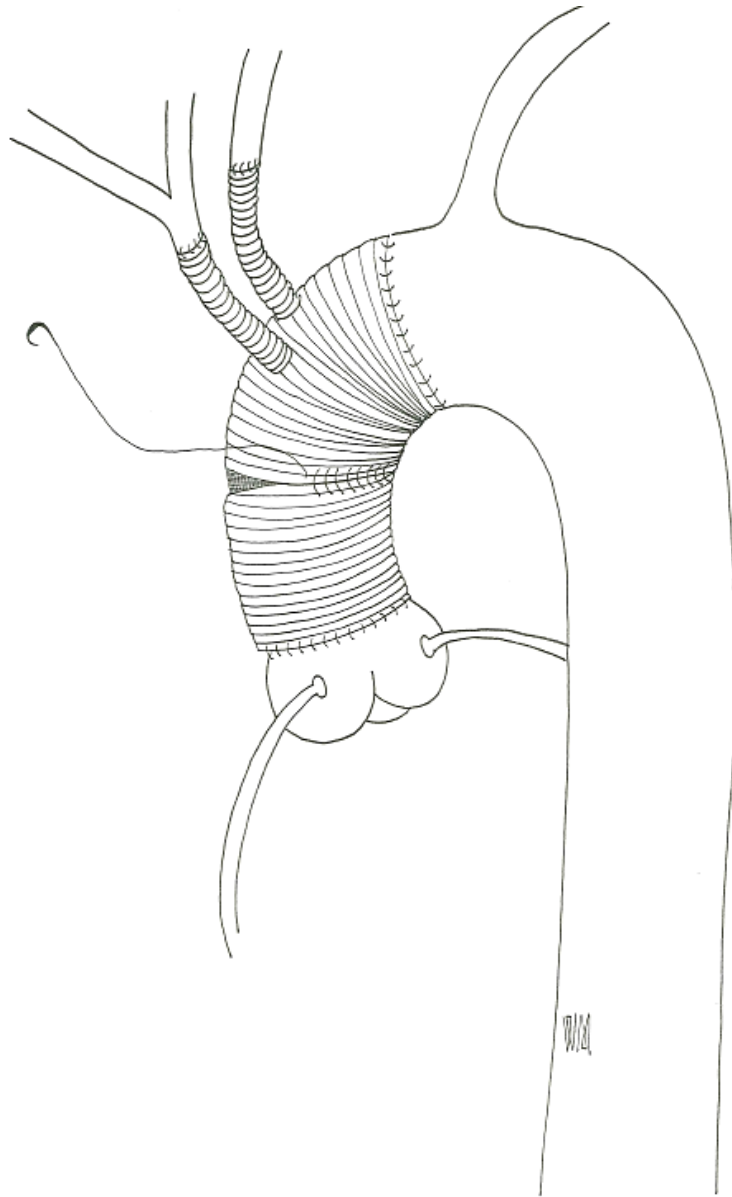
Thoracic Aorta



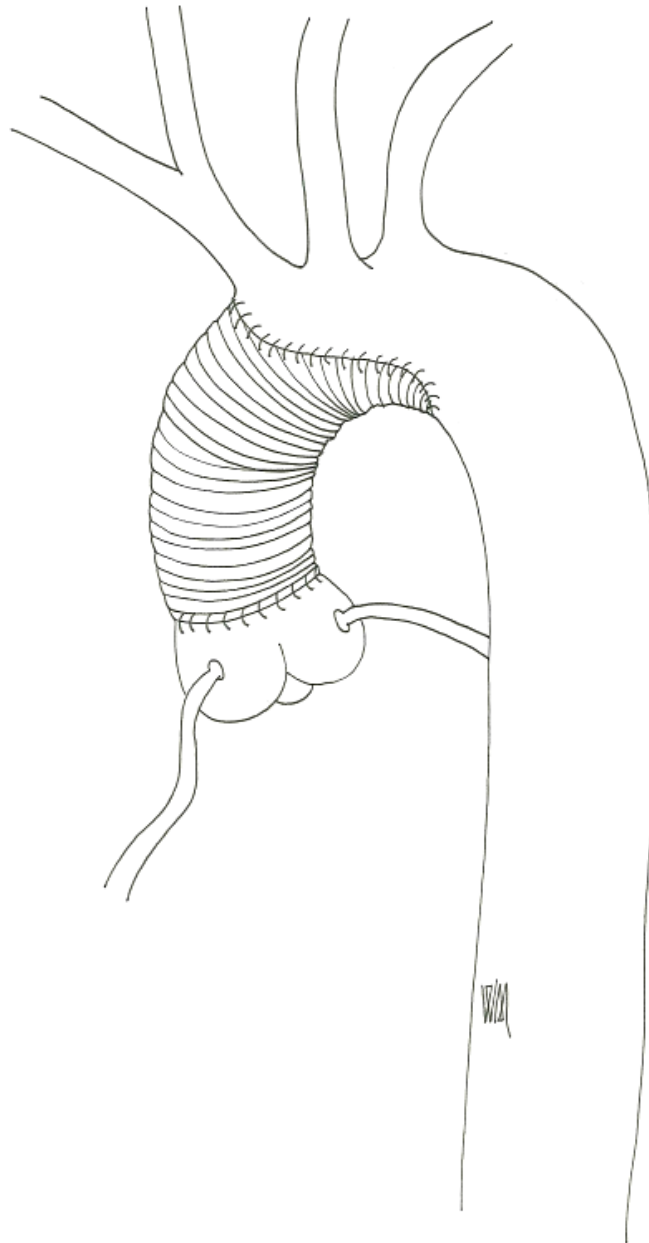
Ascending Hemiarch with AVR




Zone 2 Arch



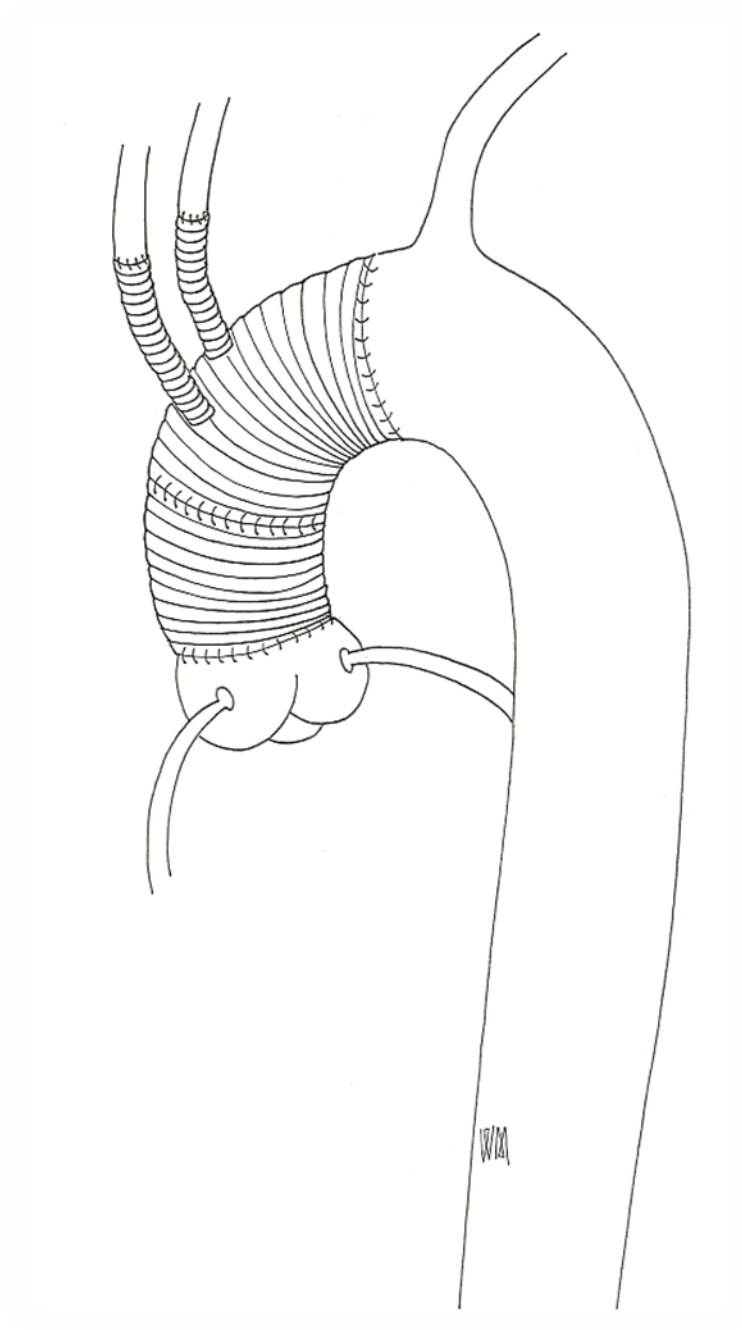
Ascending Hemiarach



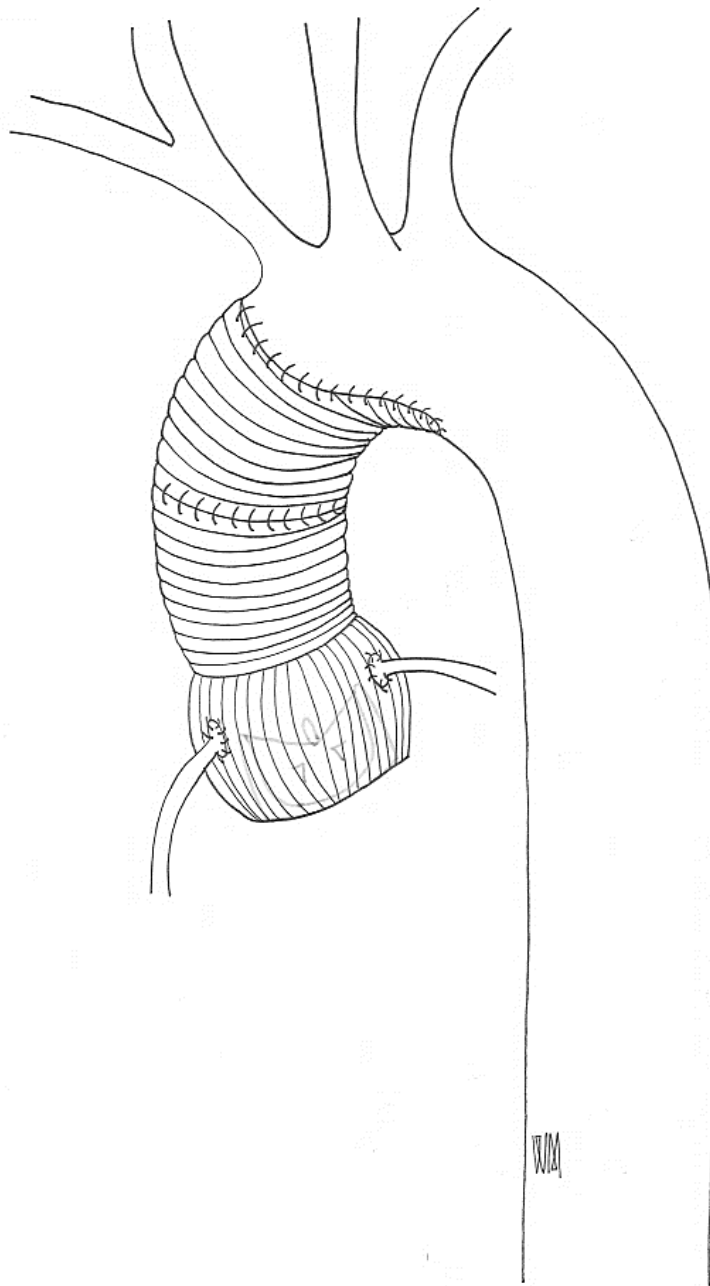
Zone 2 Arch with Frozen Elephant Trunk



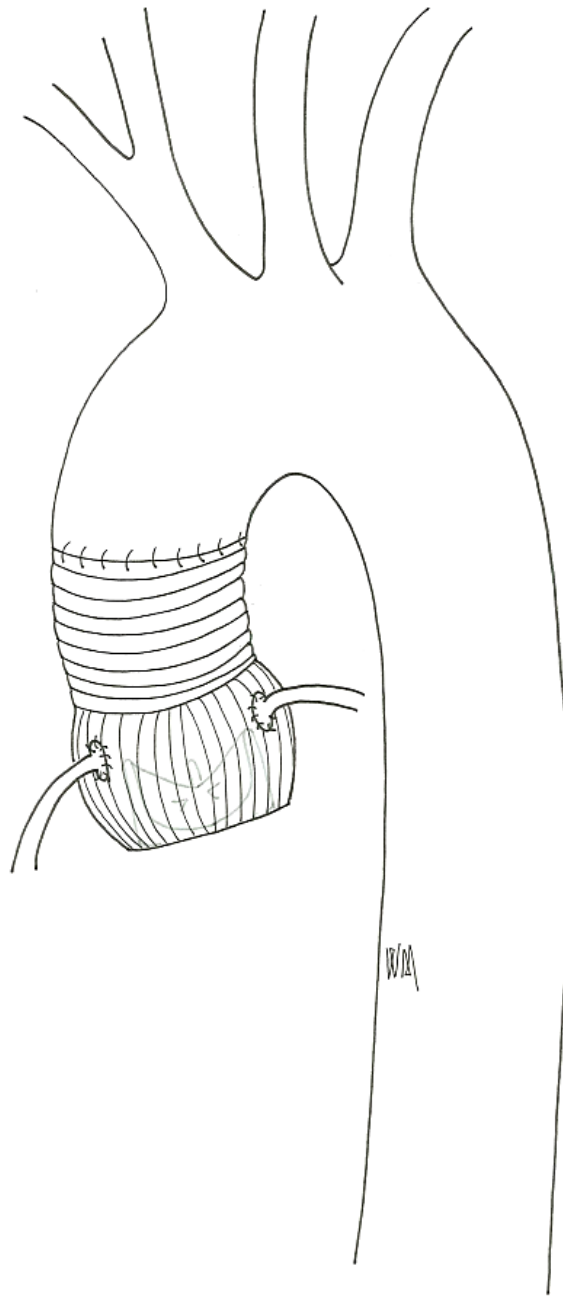
Zone 2 Arch



Bentall with Hemiarch



Bentall Procedure



David V Procedure

